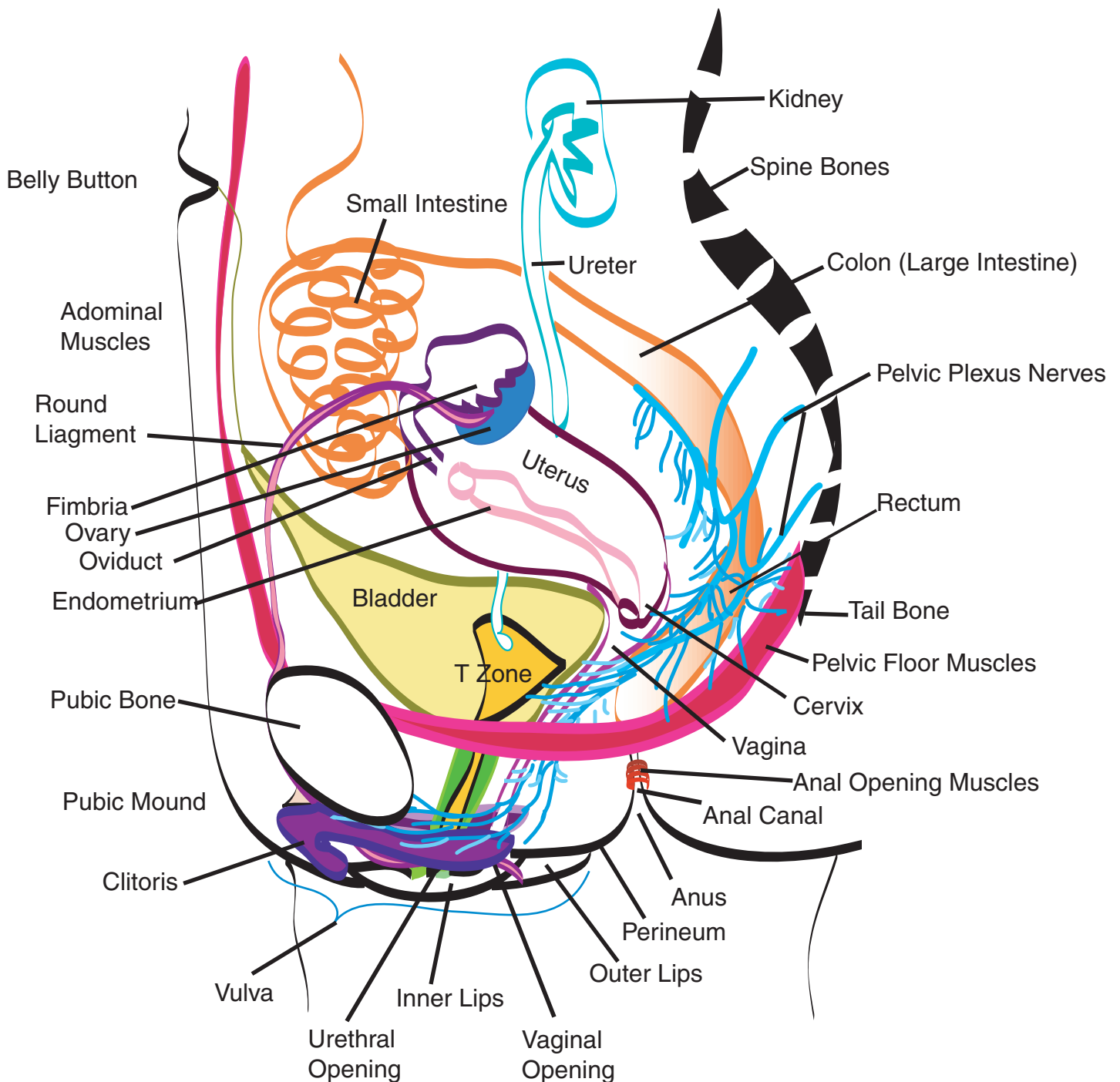


Adult Woman's Pelvic Sexual Anatomy



Components of Vulva: Outer Lips, Inner Lips, Clitoral Hood, Head of Clitoris (corpus cavernosa), Urethral Opening, Vaginal Opening, Perineum, and Major & Minor Vestibular Glands (not shown).
Nerve system of arousal = Pelvic Plexus.

Components of Reproductive System: Ova, Fimbria, Oviduct, Endometrium/Uterus, Cervix, Vaginal Canal, Vaginal Opening. Women are unresponsive to spinal nerve T12-L2 stimulation.

Components of Urinary System: Blood is filtered in Kidneys, drains by ureter to Bladder, released through urethra to urethral opening. Paraurethral secretions keep urethra open.

Components of Digestive System: Small Intestine, Colon (large intestine), Rectum, Anal Canal, Anus.