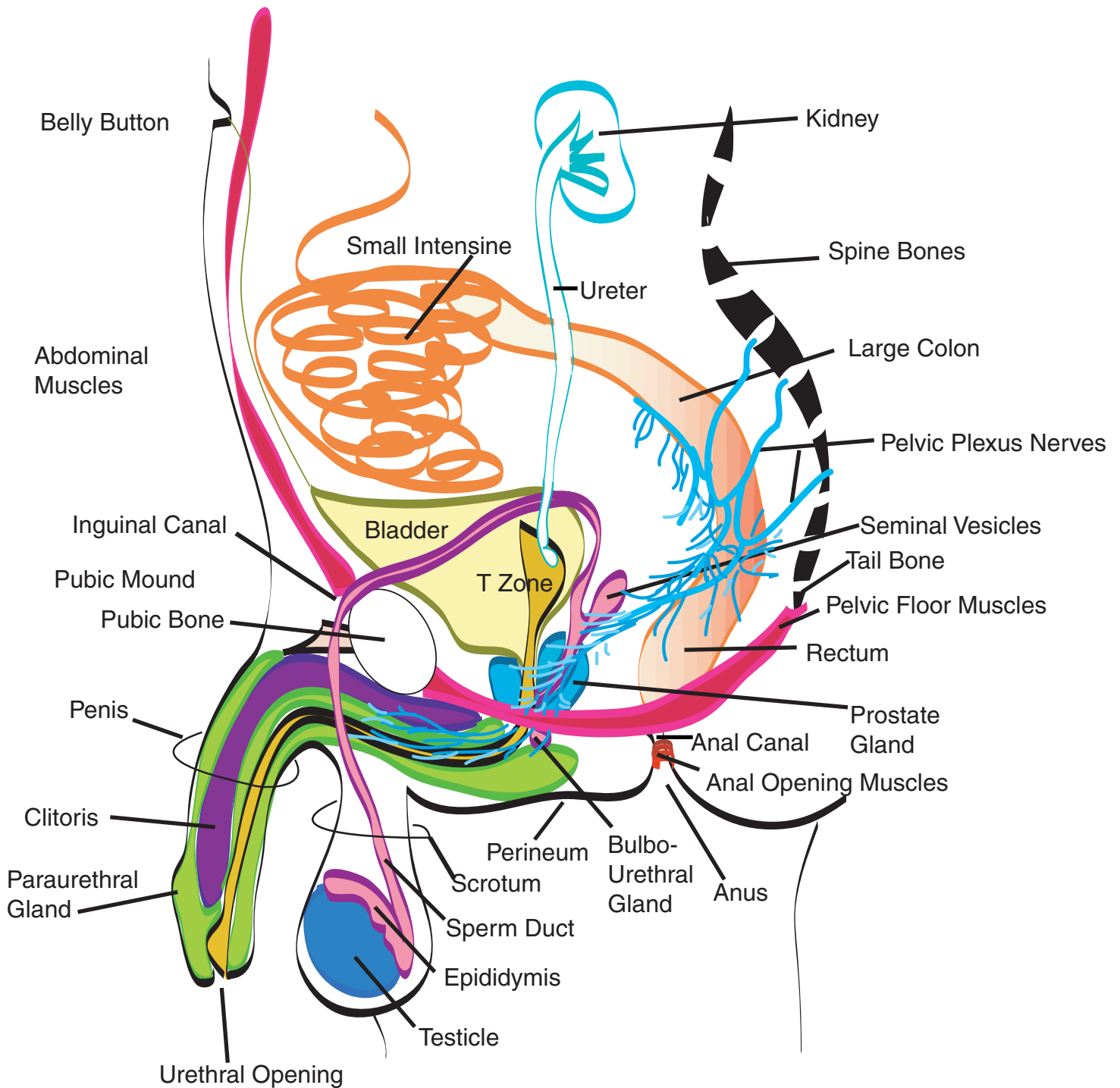


Adult Man's Pelvic Sexual Anatomy



Components of Penis: Skin, Foreskin, Penis head, Clitoris (Corpora Cavernosa), Paraurethral Gland (Corpus Spongiosa), Urethra. Nerve system of arousal = Pelvic Plexus.

Components of Ejaculatory System: Sperm (made in testicle, mature in epididymis), Sperm duct, Seminal Vessicle, Prostate Gland, Bulbourethral Gland, Urethra. Nerve System of Ejaculation = Spinal nerves T12-L2.

Components of Urinary System: Blood is filtered in Kidneys, drains by ureter to Bladder, released through urethra to urethral opening. Paraurethral secretions keep urethra open.

Components of Digestive System: Small Intestine, Colon (large intestine), Rectum, Anal Canal, Anus.